

Appendix B

Case Study Series

This appendix documents a series of thermographic images collected for a volunteer diagnosed with epilepsy. Interestingly, this individual provided much of the impetus for pursuing the thermographic study of epilepsy patients using the Cayce model. During the background research phase of the epilepsy project this woman made herself available to one of our researchers for a crude temperature measurement of her abdomen using a simple thermometer. The researcher recorded thermal data in a grid format that clearly demonstrated a cold area on the right side of the abdomen as described by Edgar Cayce.

When the Flexitherm liquid crystal thermometry (LCT) system became available, this volunteer provided further data in the series of abdominal thermographic images that follow in this appendix. The initial LCT session occurred on June 18, 1994. Note that in the images for that data the first image has a “spotchy,” irregular appearance due to a damaged screen (screen 31). All subsequent LCT images were taken using screen 30 which is one degree centigrade lower in its range but produces a much more consistent image.

Note that even in this initial session a distinctive thermal pattern is present in the lower right quadrant of the abdomen in both images. The location and shape of the cold spot using screen 31 is essentially the same as with screen 30. This helps to eliminate the possibility that any consistent pattern observed using screen 30 is due to the unique properties of that screen. This technical point was confirmed later when screen 30 was used for epilepsy patients and numerous other research participants (both normal and with diverse disorders). Although a great deal of variability was found in the thermal patterns of volunteers, the uniqueness of the patterns found in this case series and with some of the other epilepsy patients cannot be attributed to the use of screen 30.

Also note that in most of the sessions the first image is darker and less distinct than later images in that session. The reason for this variation is the use of an alcohol swab procedure whereby alcohol is gently rubbed over the entire abdomen. After a few moments that allows the alcohol to evaporate, another LCT image is taken. The rationale for this procedure is that the evaporating alcohol cools the abdomen quickly and may produce a more distinct image. This does seem to be the case as the later images in some sessions (i.e., after the alcohol rub) tend to be brighter and more distinct. Subsequently, we included this technique as part of the infrared thermography phase of the epilepsy research program.

About thirteen months after the initial LCT session, a series of LCT thermographic images were taken over a four-month period in 1995. The volunteer was seeing one of the Meridian clinical researchers as a patient and was willing to have the LCT images taken. The LCT procedure was incorporated into the clinical routine, prior to treatment, but without any special attention to room temperature or equilibration period.

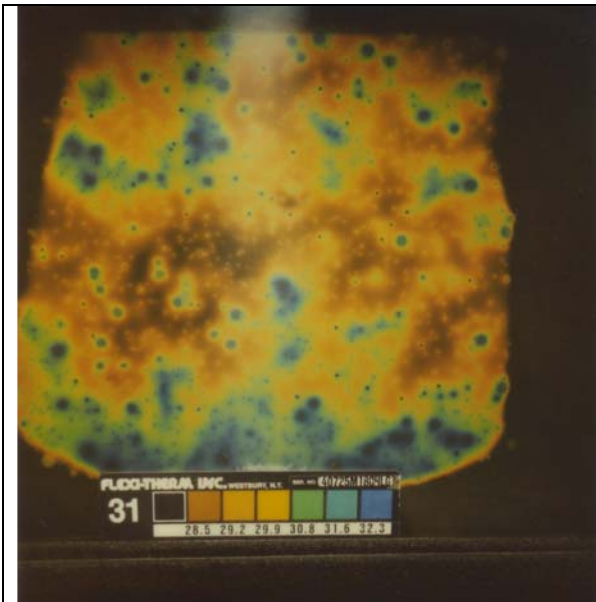
Note the following points about these series of LCT images:

- There is considerable variability in the thermal images, yet the basic thermal patterns can be consistently observed.
- The distinctive cold spot in the lower right quadrant of the abdomen is present to some extent in every image, although at times the feature is very subtle.
- The shape of the cold spot can be described as circular with a protrusion from the bottom. This is interesting since the LCT images from some other epilepsy patients exhibit a similar configuration.
- There are cold areas in other parts of the abdomen.

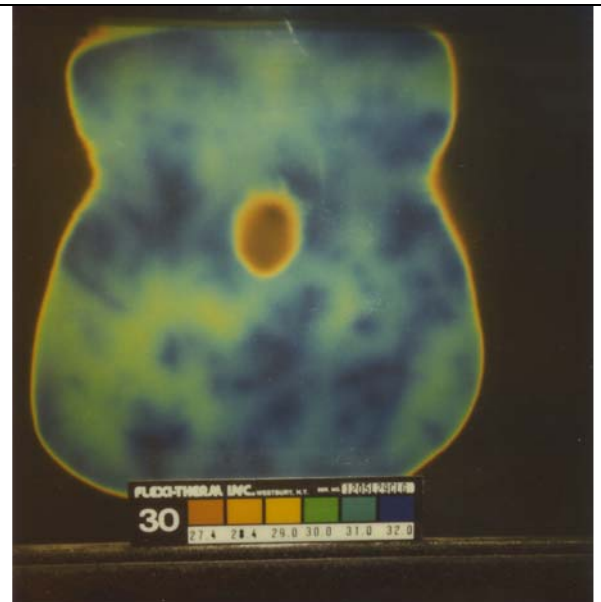
Keeping in mind that some of the Cayce readings stipulated that the cold spot in epilepsy would only be detectable in temporal relation to a seizure (i.e., just before, during, or

immediately after – see Appendix A), one might expect a high degree of variability in abdominal thermal images in epilepsy patients. In other words, a single thermographic session could not necessarily rule out the possibility of an abdominal cold spot for a given patient. Given limited research resources, a reasonable procedure would be to do screening sessions for many patients and then do a series of repeat sessions with patients exhibiting at least an indication of a cold spot on the right side of the abdomen. For example, if the September 13, 1995 session were the only sample taken for this individual, the conclusion might be that this participant does not exhibit an abdominal cold spot.

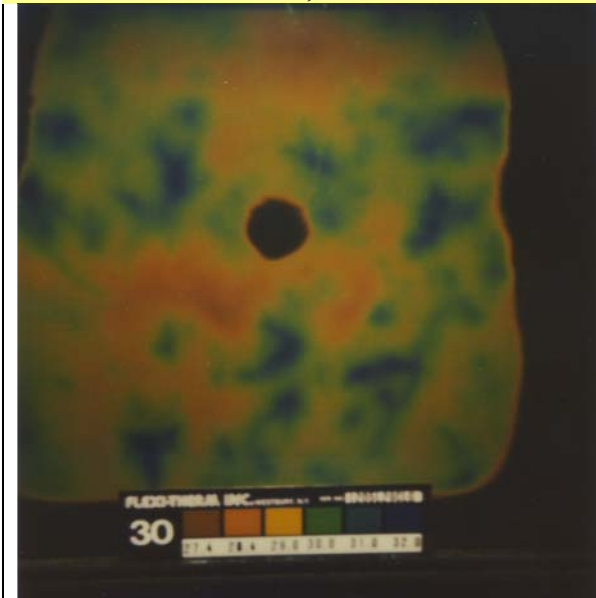
The discussion section of the report explores the impact of variability of the cold spot in our research outcomes and provides suggestions for dealing with this problem.



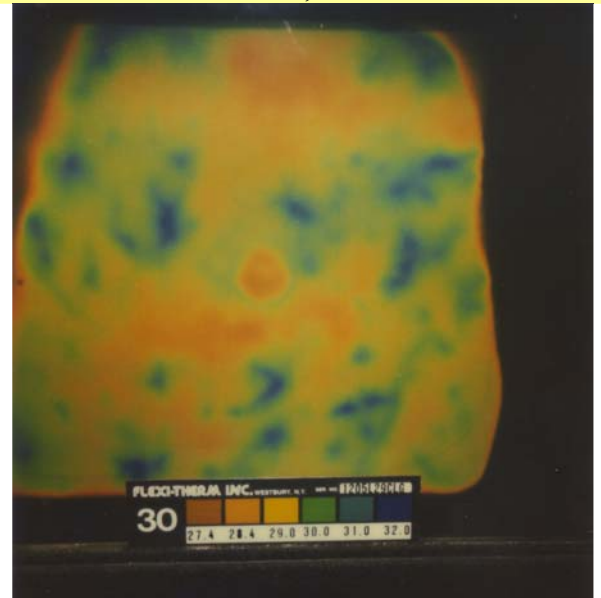
June 18, 1994 a



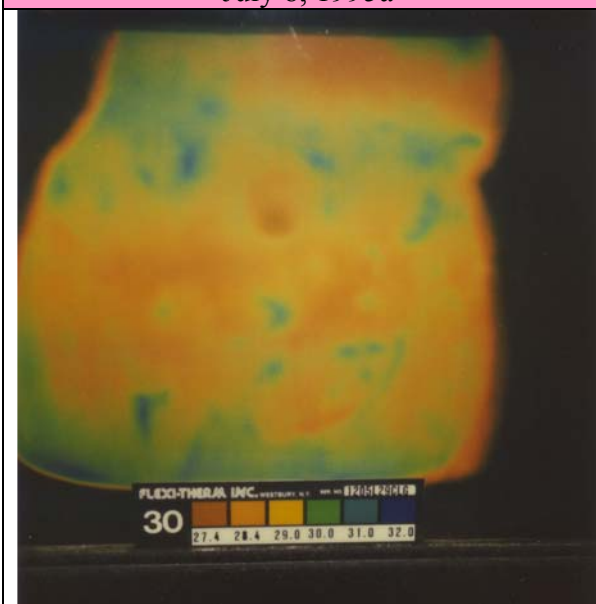
June 18, 1994b



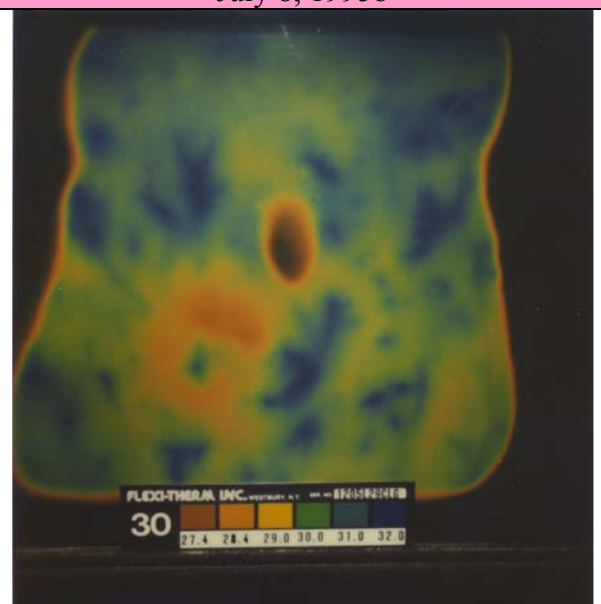
July 8, 1995a



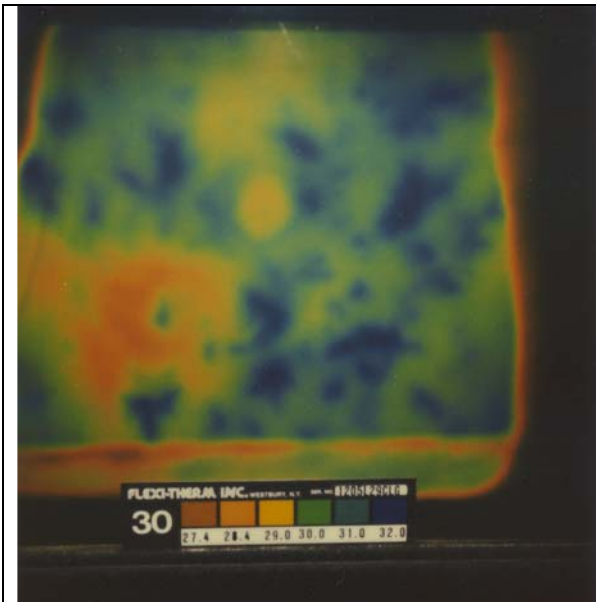
July 8, 1995b



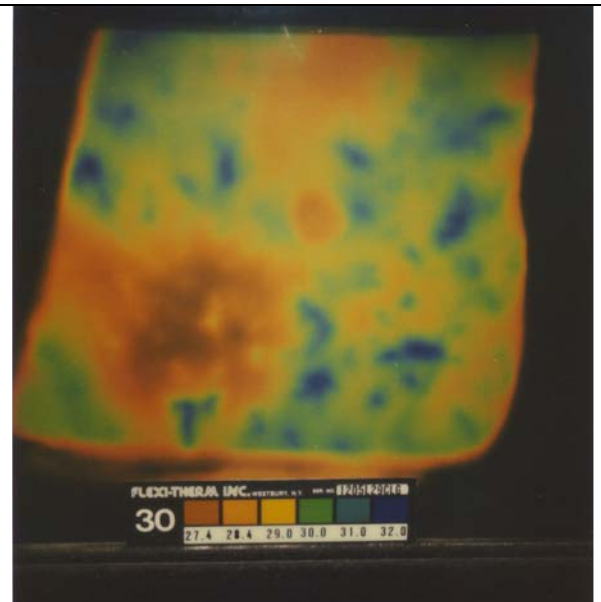
July 8, 1995c



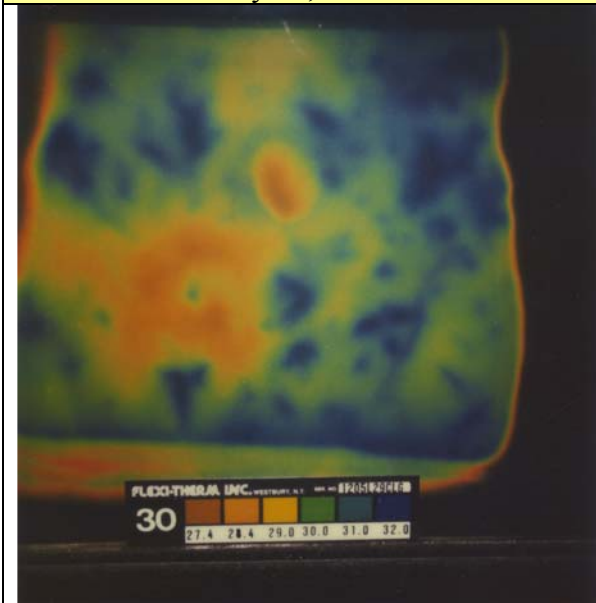
July 12, 1995



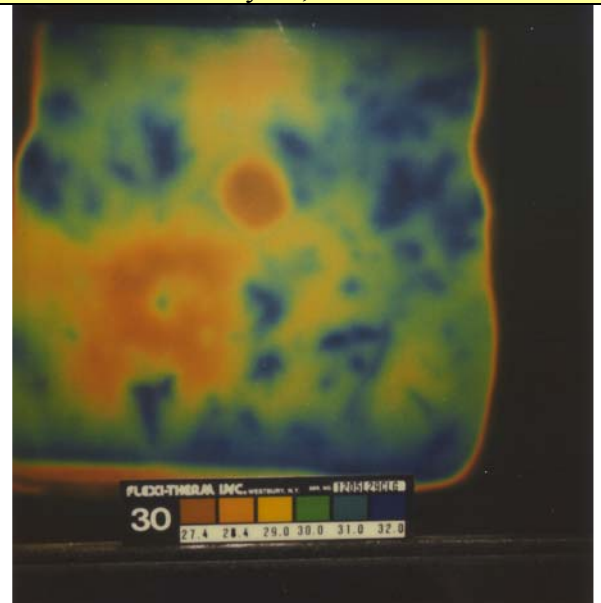
July 19, 1995a



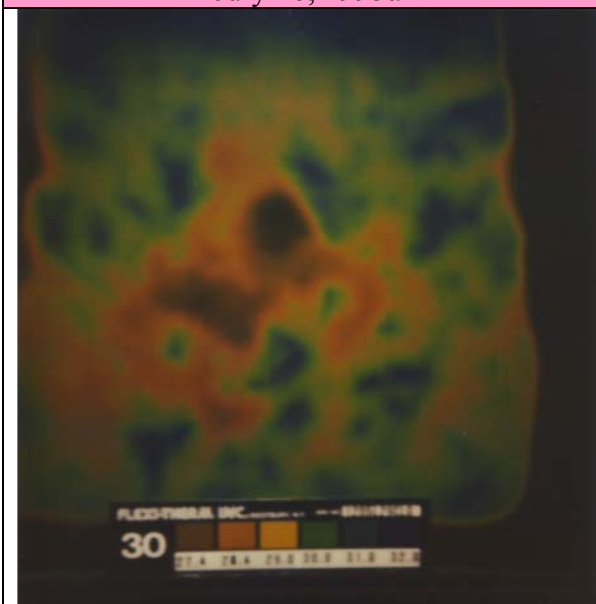
July 19, 1995b



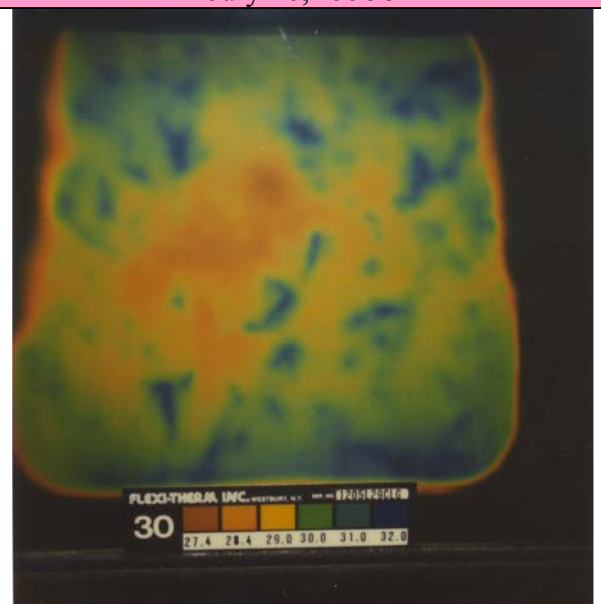
July 26, 1995a



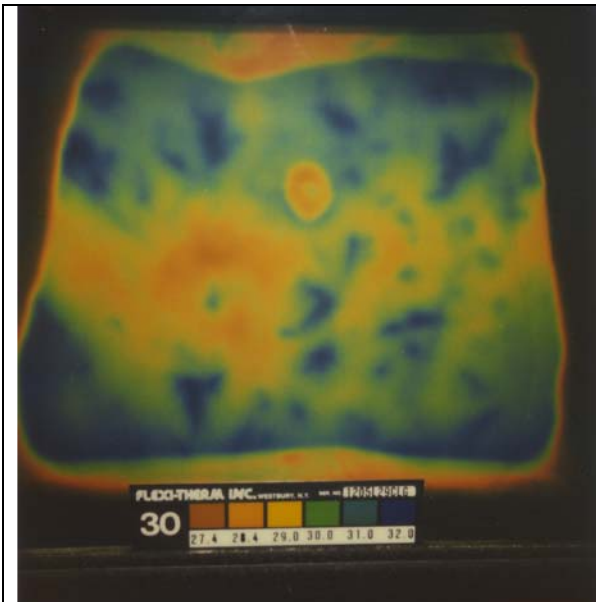
July 26, 1995b



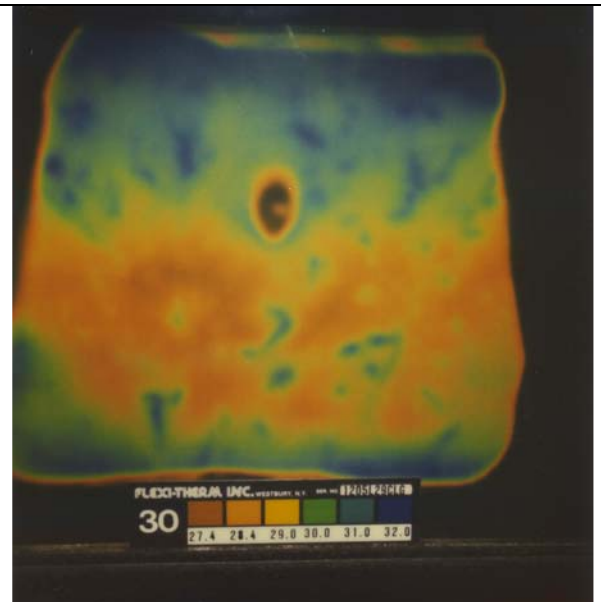
August 2, 1995a



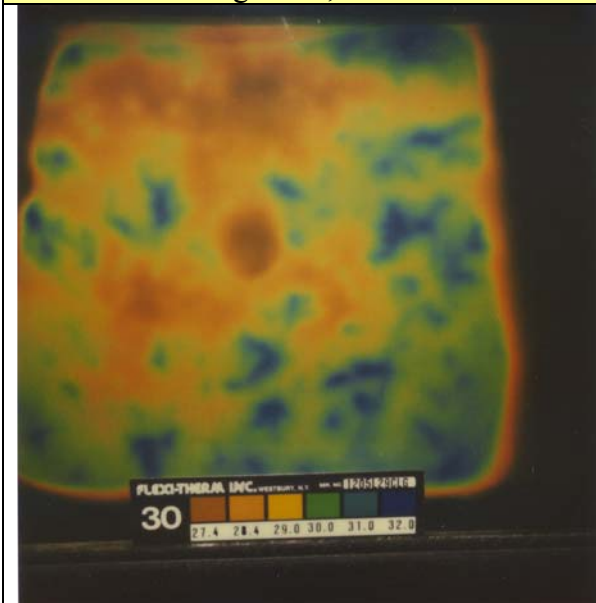
August 2, 1995b



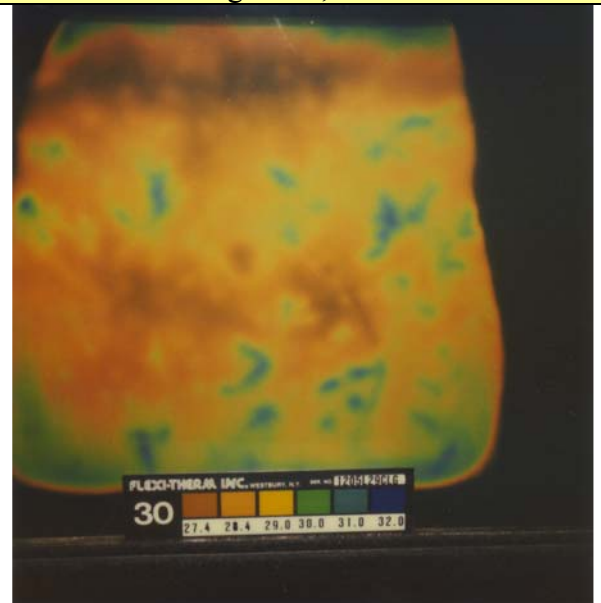
August 16, 1995a



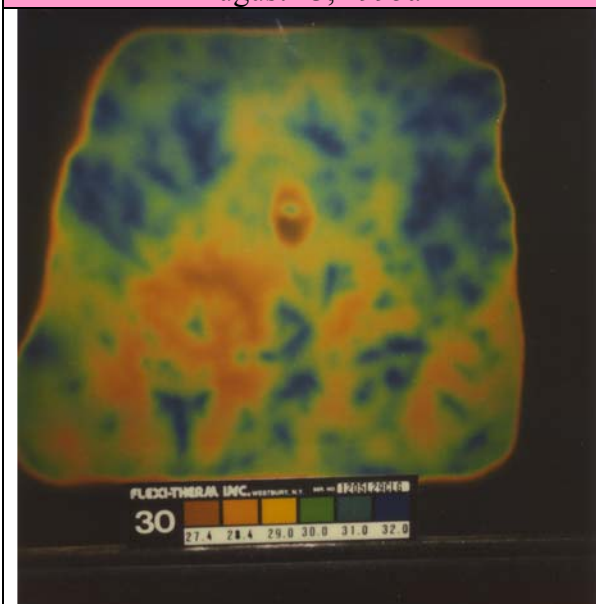
August 16, 1995b



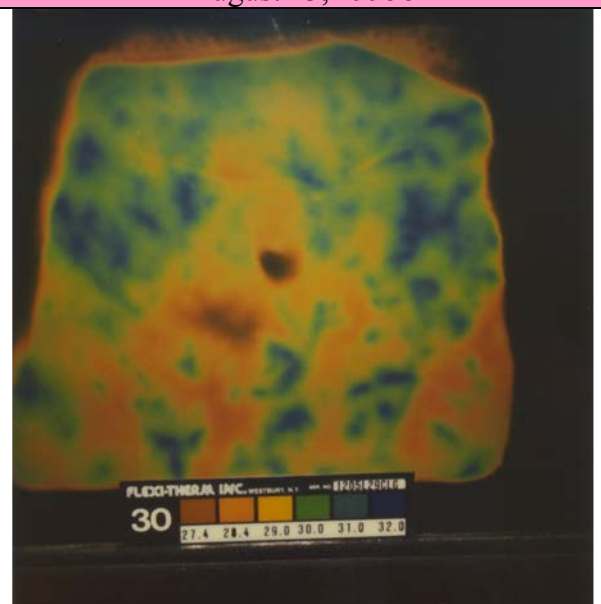
August 23, 1995a



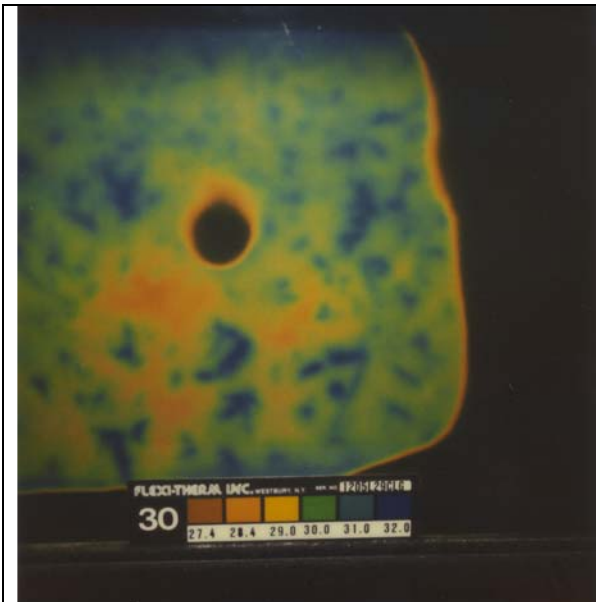
August 23, 1995b



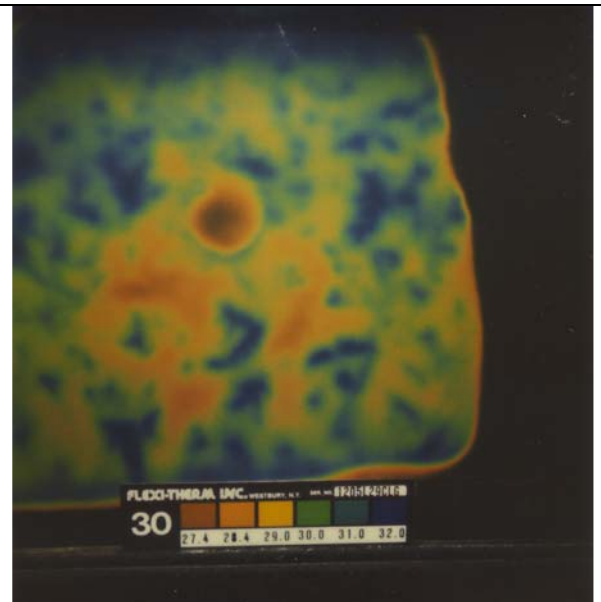
August 30, 1995a



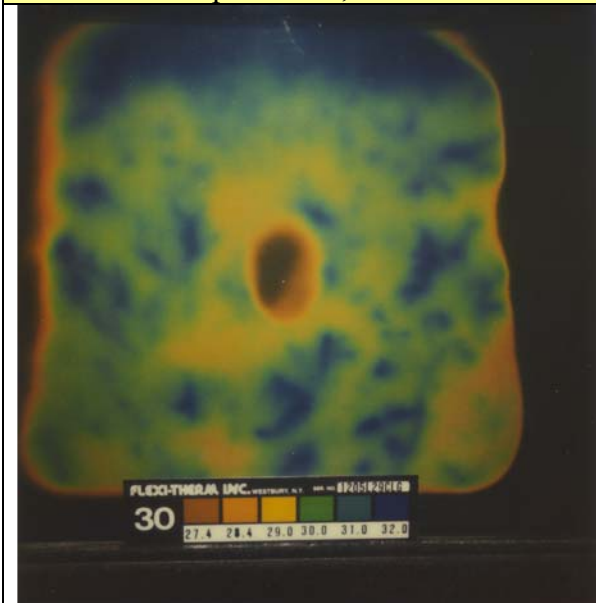
August 30, 1995b



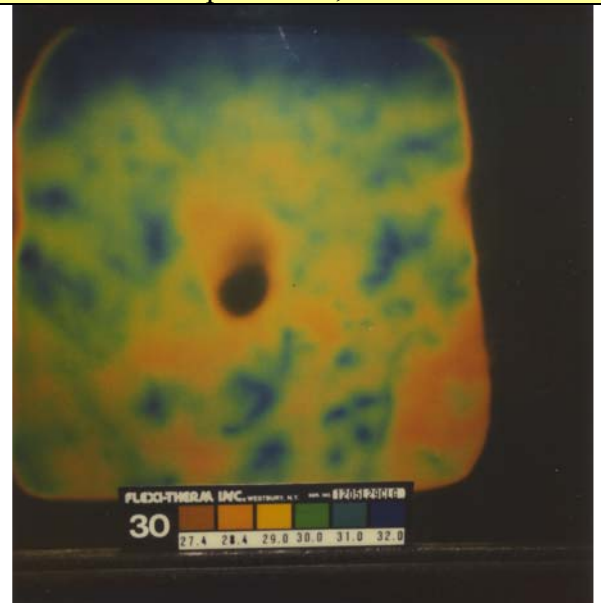
September 6, 1995a



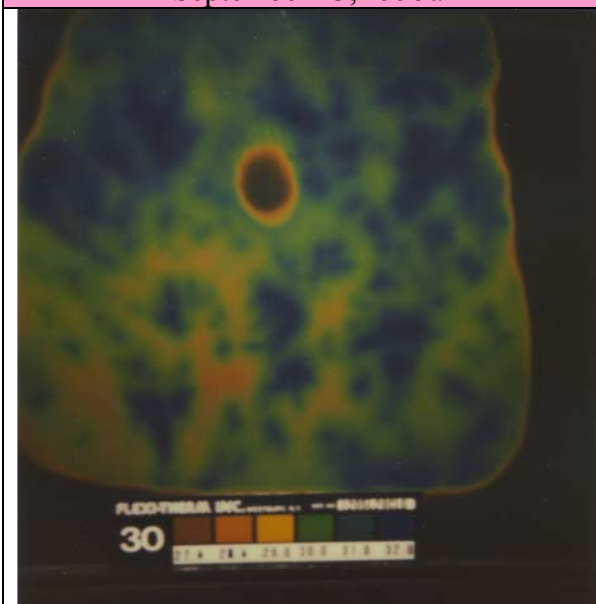
September 6, 1995b



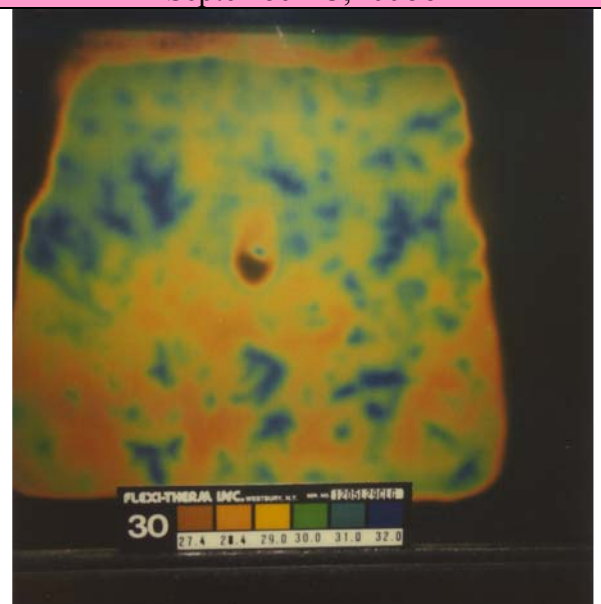
September 13, 1995a



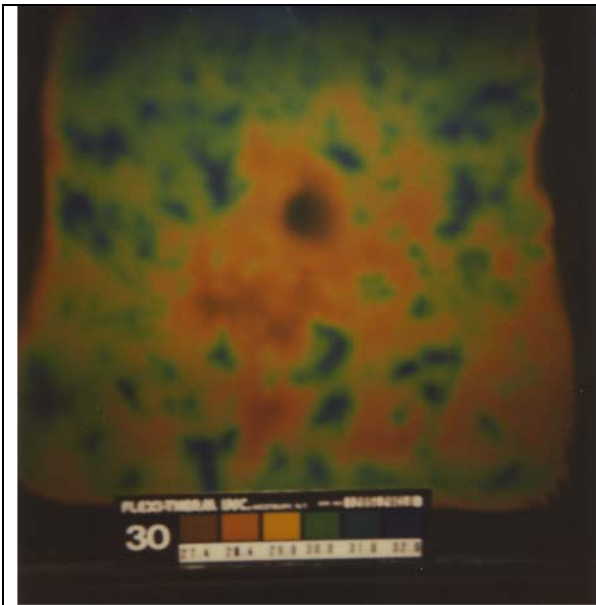
September 13, 1995b



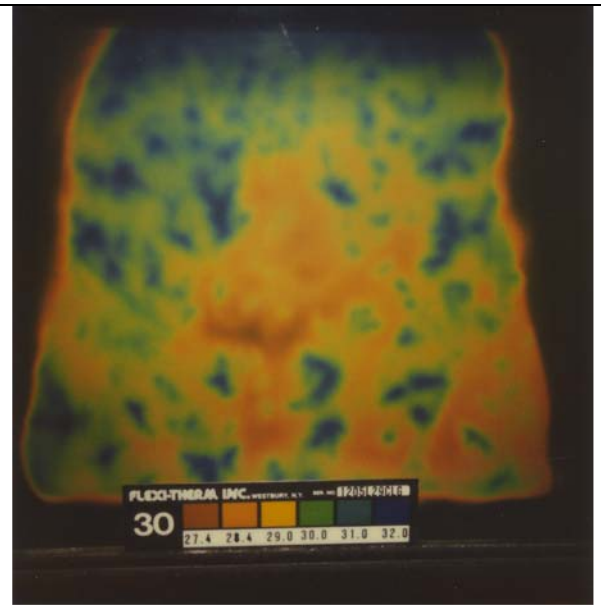
September 20, 1995a



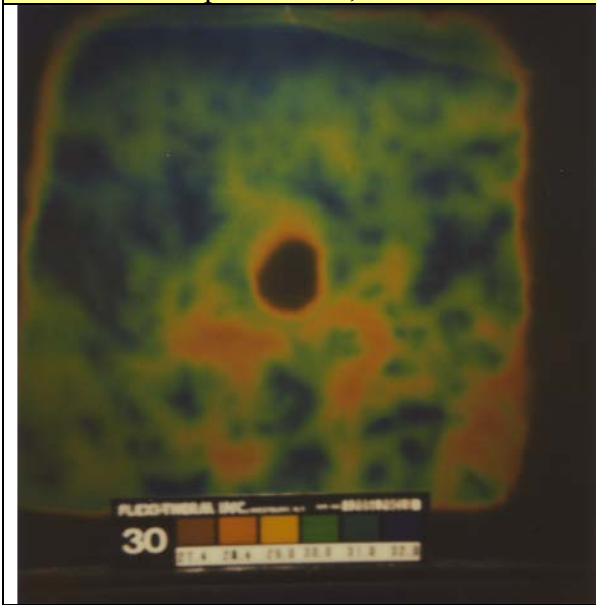
September 20, 1995b



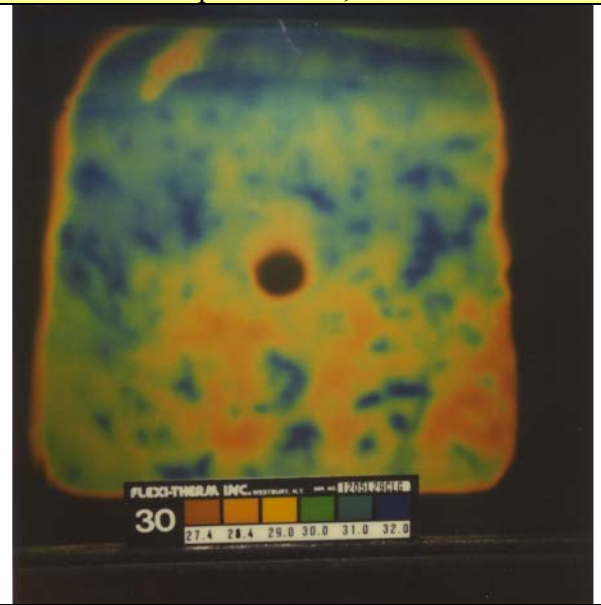
September 27, 1995a



September 27, 1995b



October 4, 1995a



October 4, 1995b